

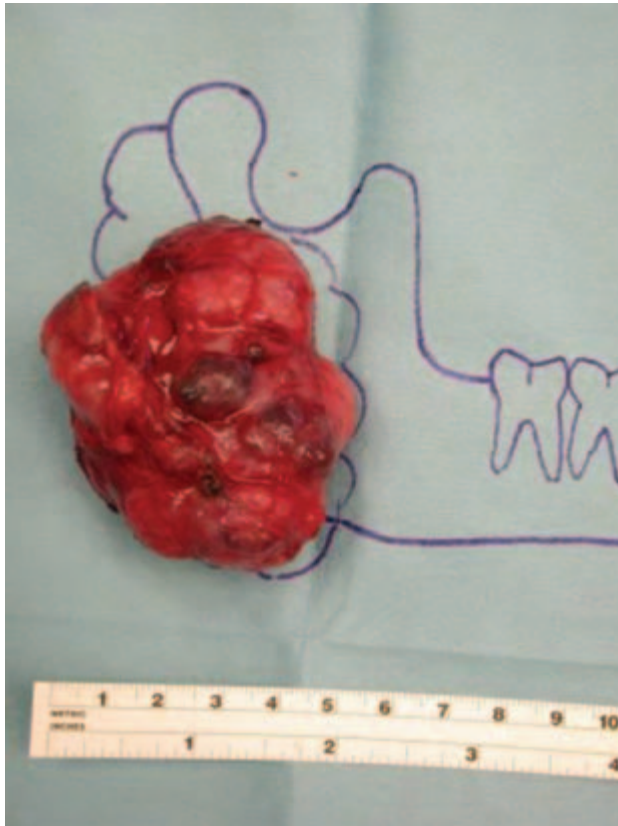Figure 8.8g. The final specimen, which was PA, seen in relation to the mandible.

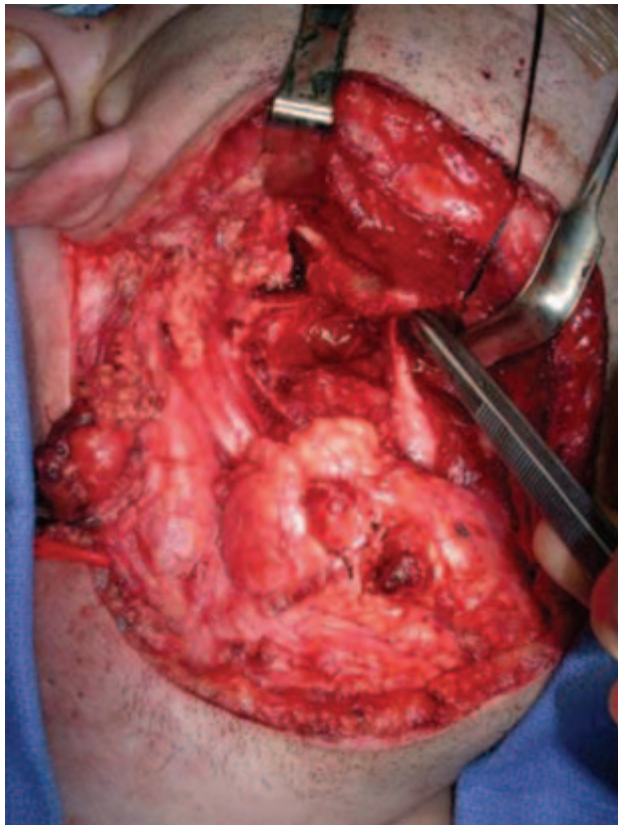


Figure 8.8h. The post-resection tumor bed. The plates are reapplied to reconstruct the original position of the mandible and occlusion.