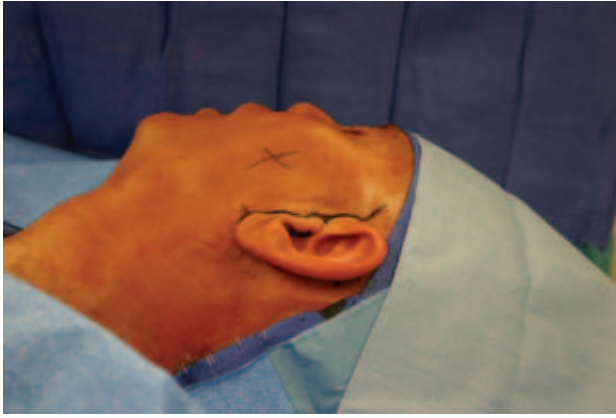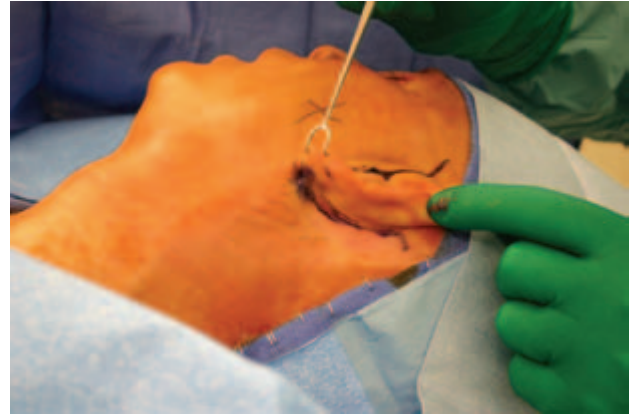
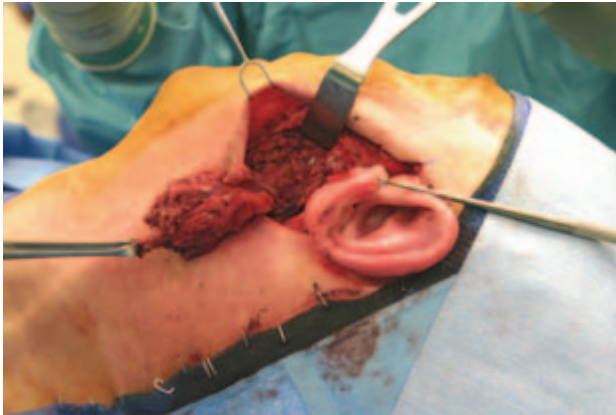




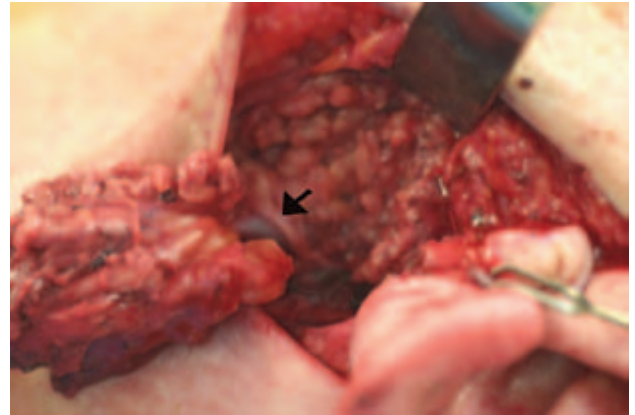
**Figure 8.6a.** Preauricular portion of omega face lift incision for parotidectomy for benign cystic lesion in the retro-mandibular portion of the superficial lobe of the left parotid gland.



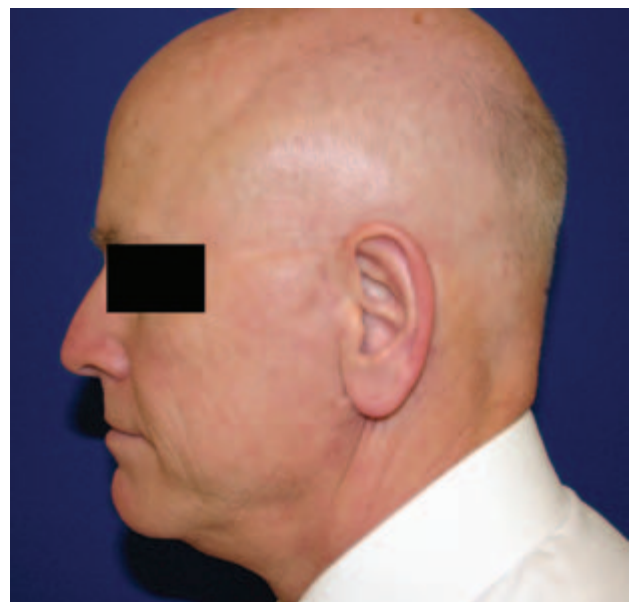**Figure 8.6b.** Post-auricular portion of omega incision runs in the post-auricular sulcus.



**Figure 8.6c.** A partial parotidectomy of the retroauricular portion of the superficial lobe is almost completed. The specimen is pedicled to the remains of the parotid tail.



**Figure 8.6d.** Close-up of the dissection. Arrow points to the mandibulo-cervical trunk, which was the only branch of the facial nerve that was dissected, as it crosses superficial to the retromandibular vein.



**Figure 8.6e.** The patient 3 months postoperatively with no visible scar.