

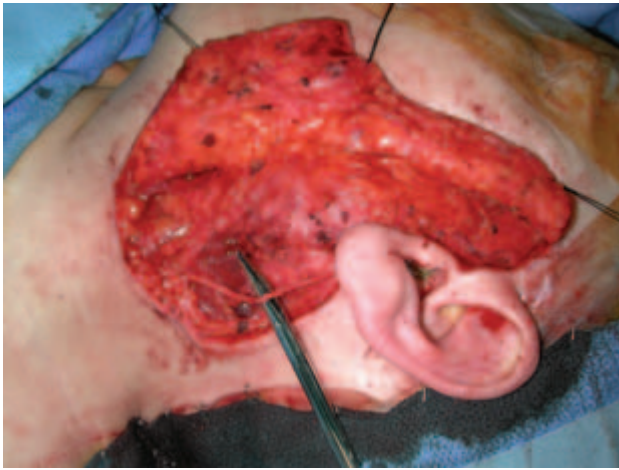

Figure 8.4e. Skin flap raised, the instrument indicates the sensory branch of the greater auricular nerve to the ear, which was preserved in this case.

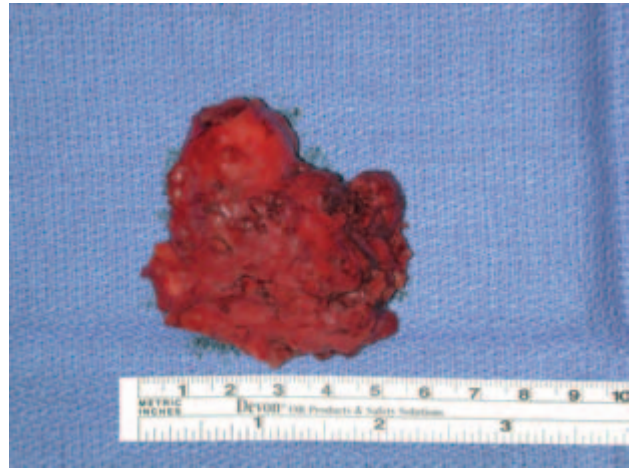

Figure 8.4g. The surgical specimen is seen with the tumor superiorly with no good surrounding "cuff" of tissue.

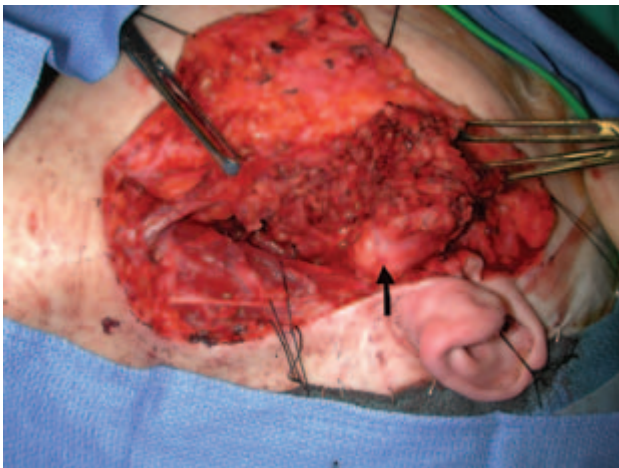


Figure 8.4f. The parotidectomy has been commenced from inferiorly and the superficial lobe is being retracted superiorly. The arrow indicates the deep surface of the tumor, which was adjacent to the nerve bifurcation (seen inferior to the tumor) and has no normal parotid tissue covering the tumor capsule.

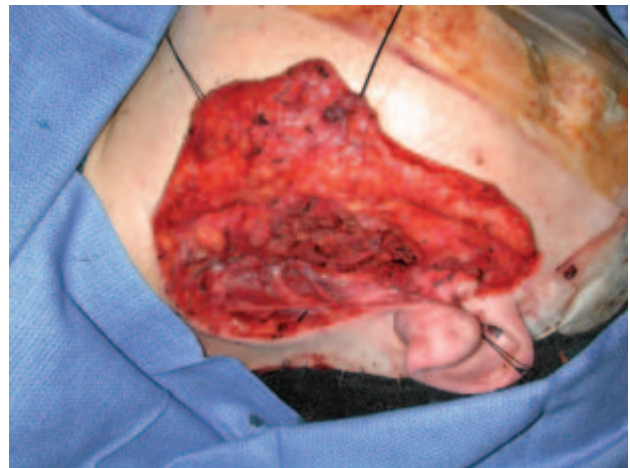


Figure 8.4h. The surgical site post-parotidectomy with complete dissection of the facial nerve.

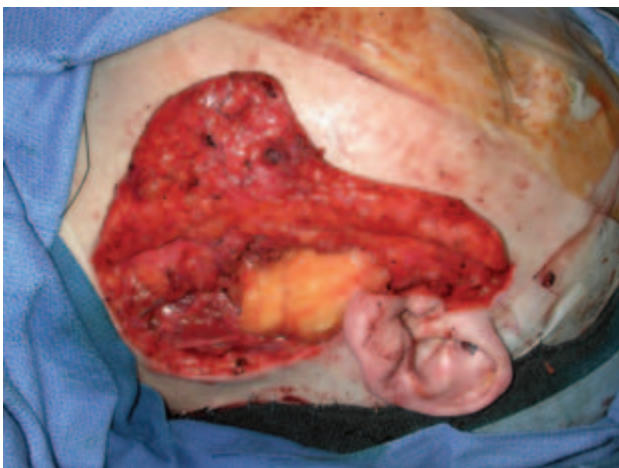

Figure 8.4i. A free abdominal fat graft is placed to reduce "hollowing," which was a concern of the patient.