

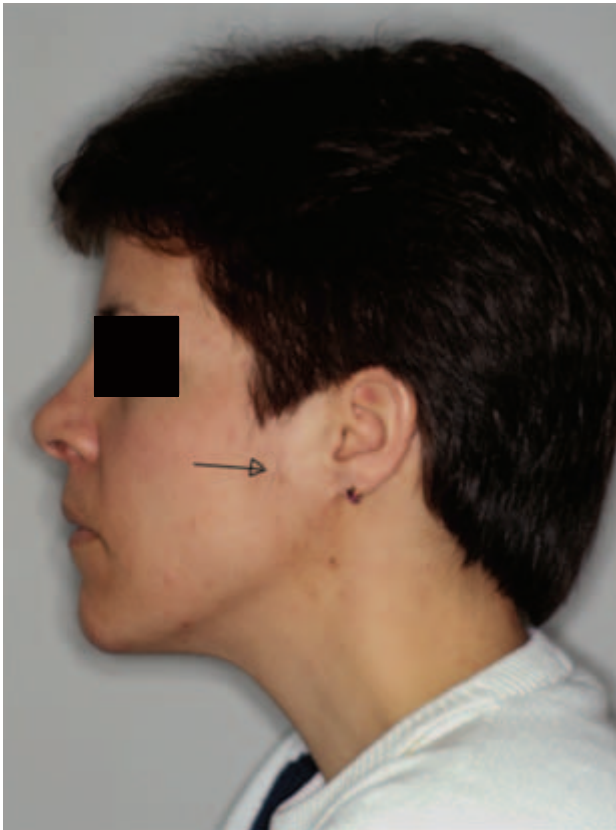Figure 8.3a. A 45-year-old woman with parotid pleomorphic adenoma biopsied through the cheek. The arrow points to the biopsy scar.

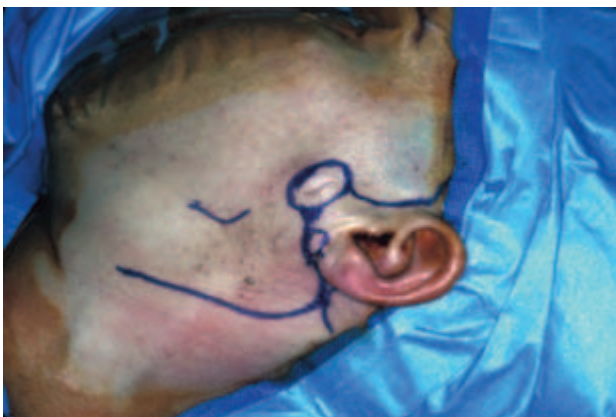

Figure 8.3b. The surgical incision is delineated and includes a 1 cm skin paddle surrounding the biopsy scar.

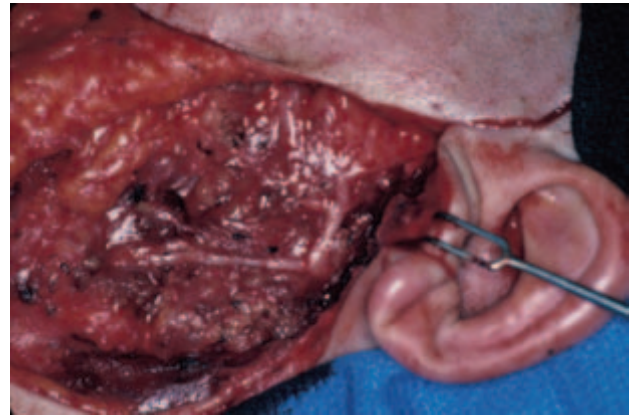


Figure 8.3c. Superficial parotidectomy with complete nerve dissection.

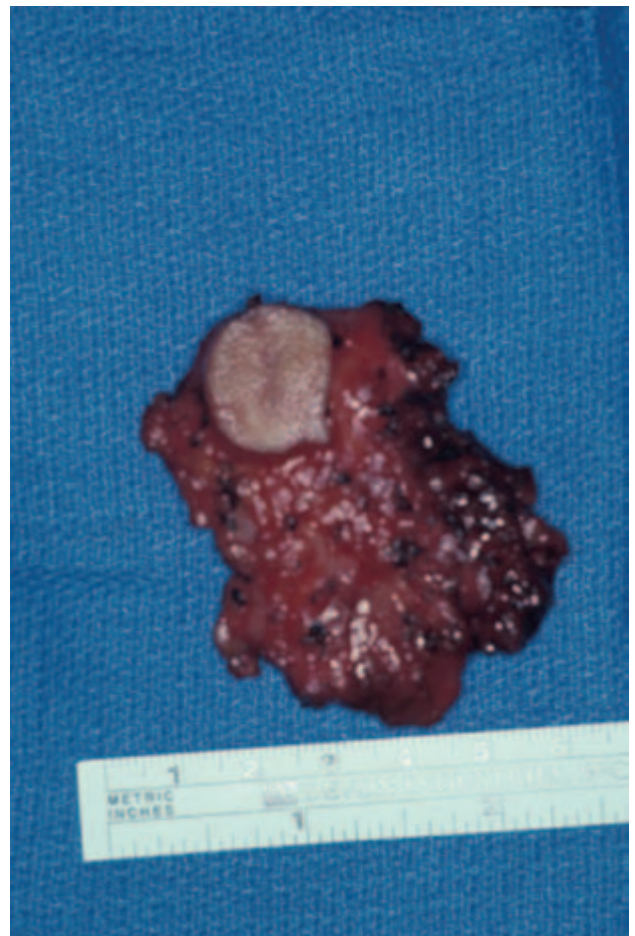

Figure 8.3d. Surgical specimen of parotid with overlying skin.