



Figure 6.1. A 36-year-old woman with a known history of Sjogren's syndrome associated with rheumatoid arthritis. She described a recent history of painful swelling of the right parotid gland such that an incisional parotid biopsy was recommended.

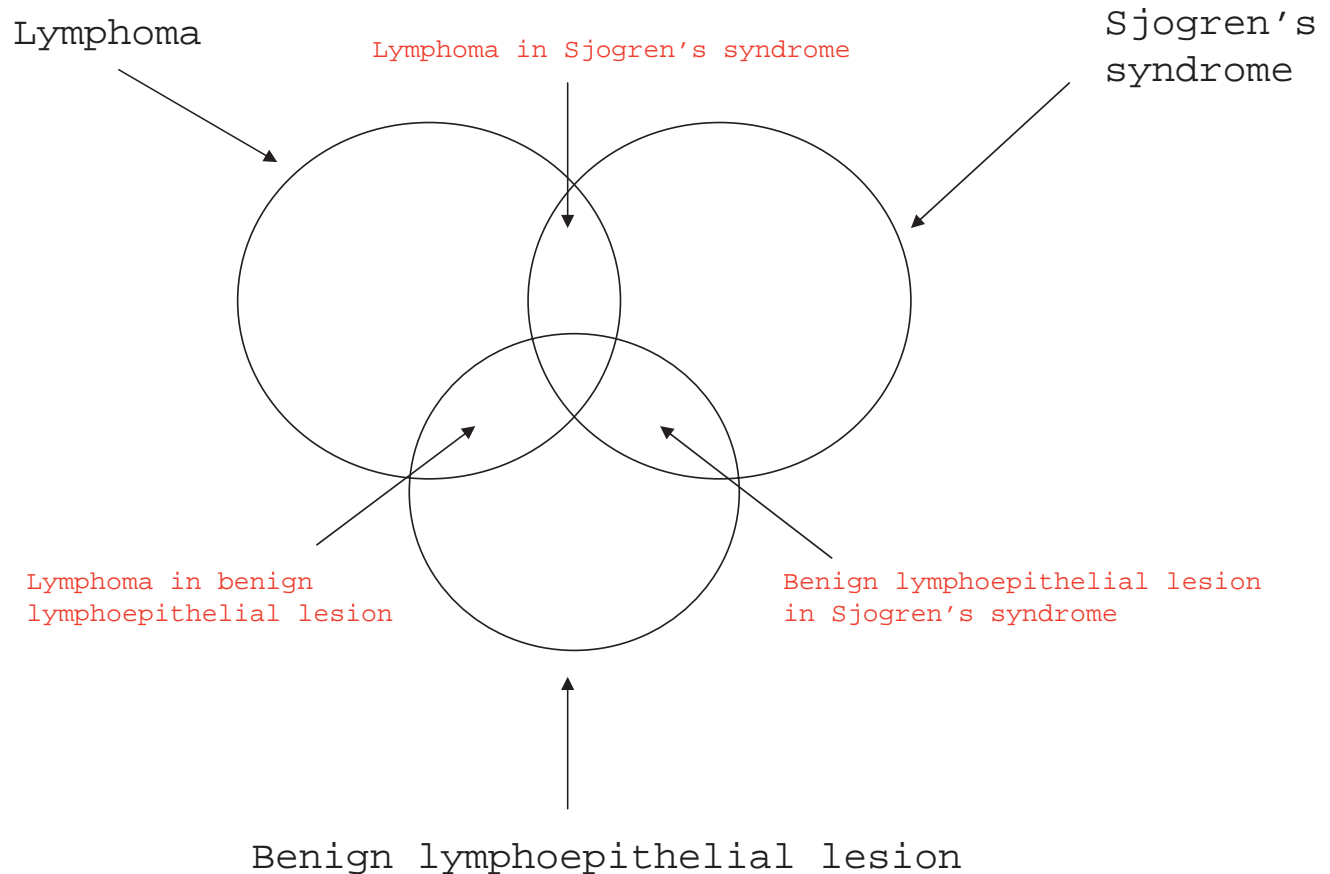


Figure 6.2. The association between the lymphoepithelial lesion, Sjogren's syndrome, and lymphoma.