

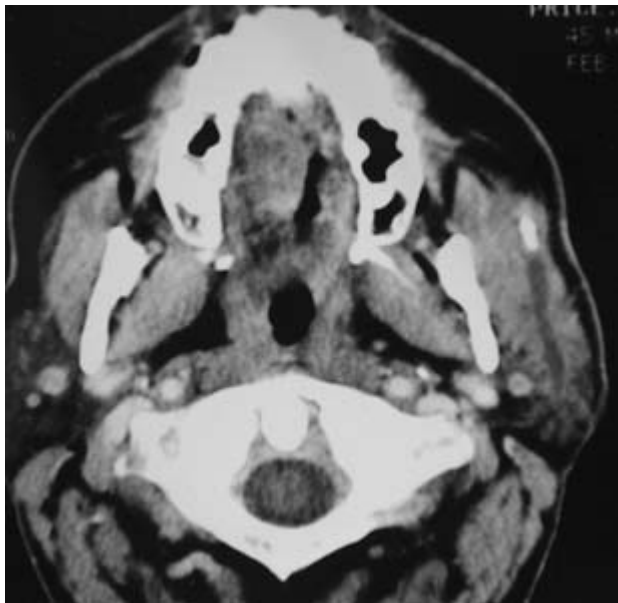Figure 5.16a. Axial CT scan demonstrating a parotid sialolith at the hilum with proximal dilatation of the duct due to obstruction of salivary flow.

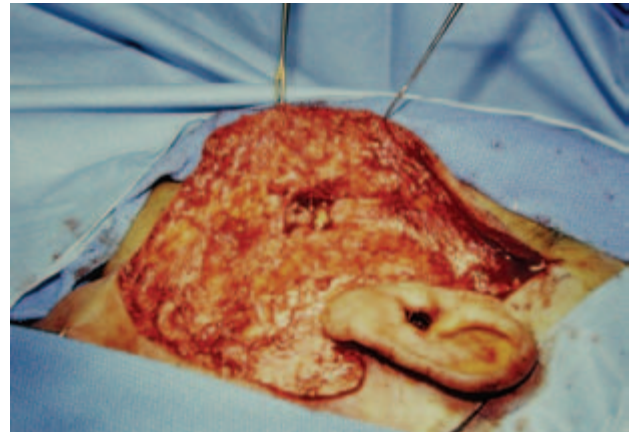


Figure 5.16b. A parotidectomy approach to stone retrieval was performed without parotidectomy.

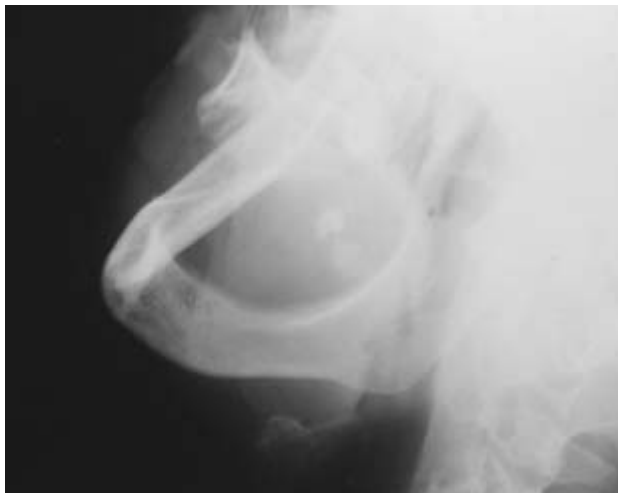

Figure 5.17a. A lateral oblique plain film demonstrating two sialoliths of Stenson's duct.

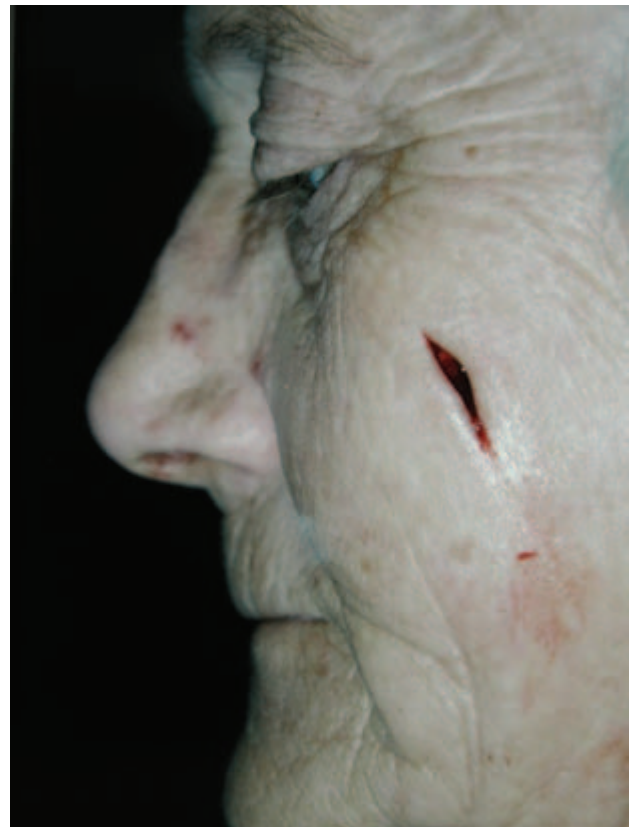

Figure 5.17b. An incision through skin was placed in a resting tension line of the cheek.