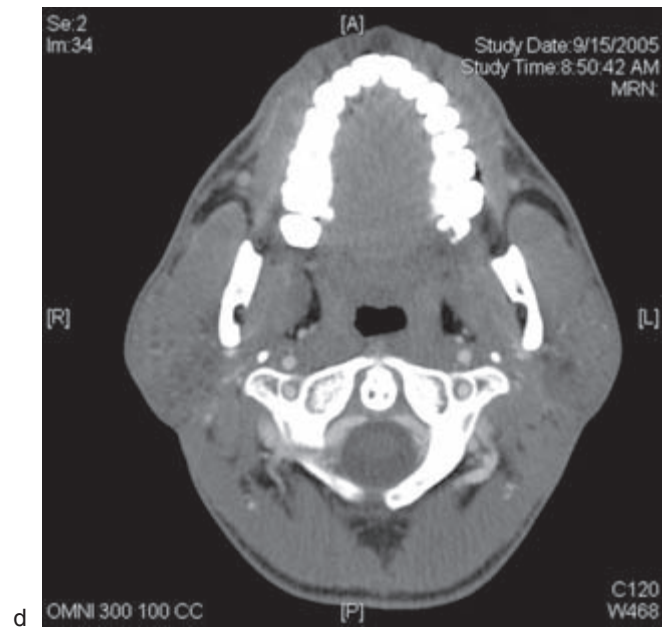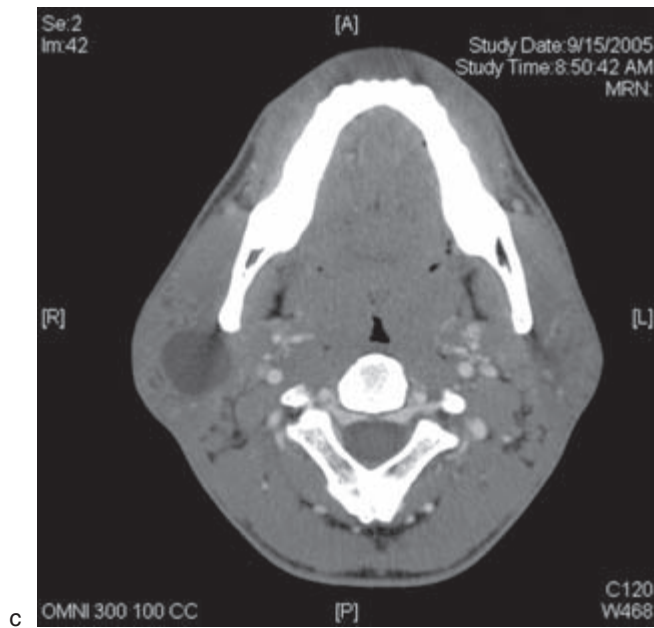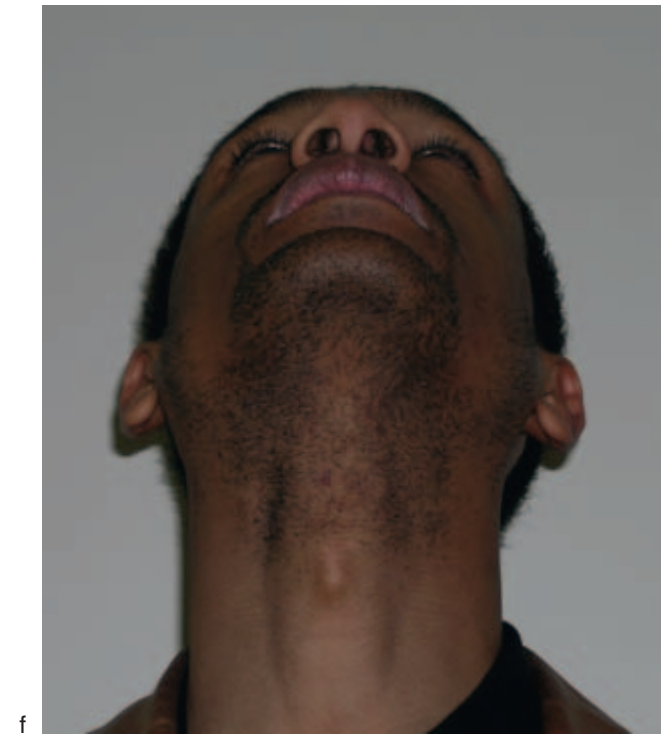


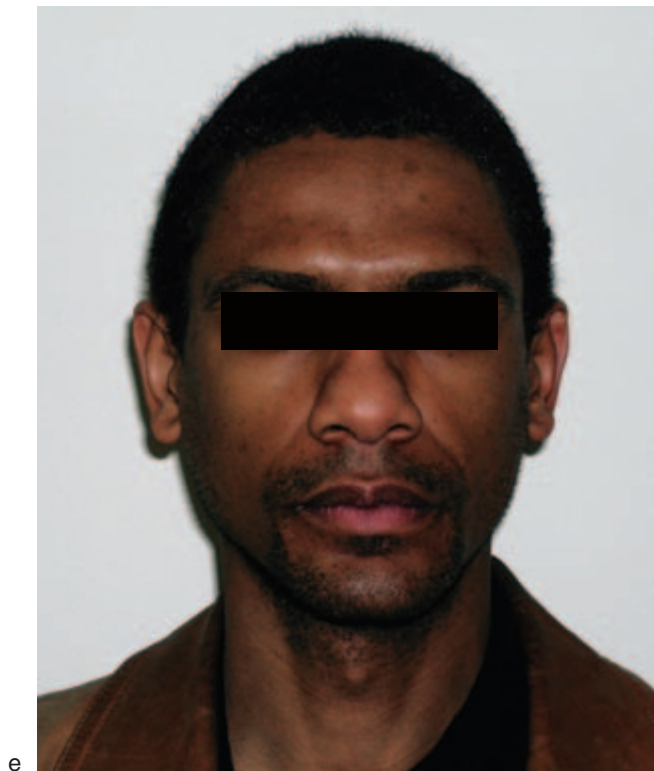**Figures 4.14c and 4.14d.** Computerized tomograms confirmed these findings. A fine needle aspiration biopsy was performed that yielded thick white fluid. A diagnosis of lymphoepithelial cysts was made.



**Figures 4.14e and 4.14f.** The patient resumed his HAART and the cysts regressed, as noted on an examination 4 months later. His CD4/CD8 was 1.12 at this time.