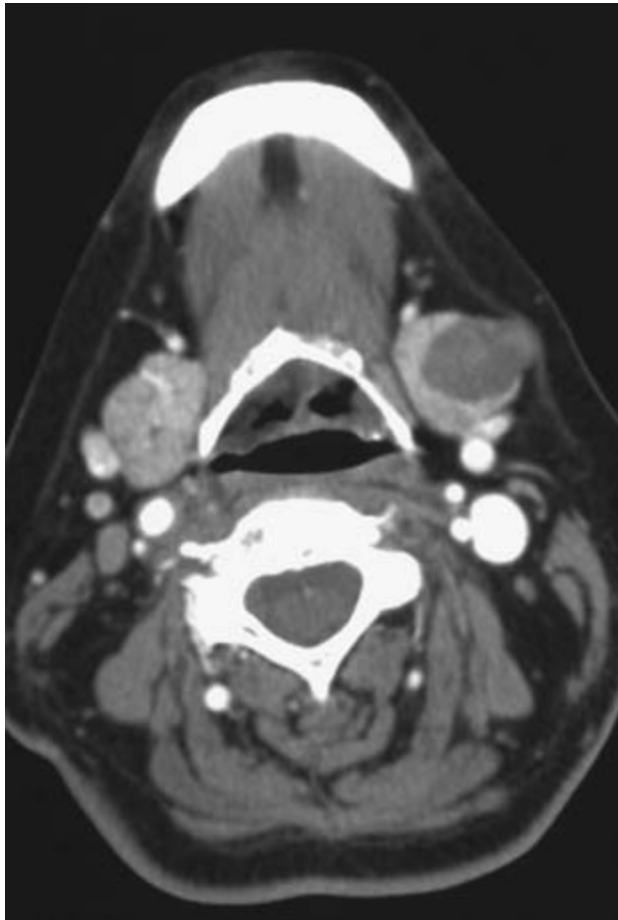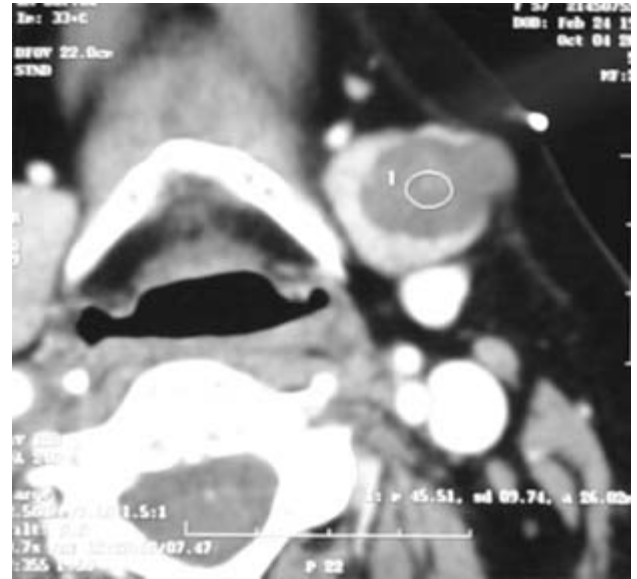

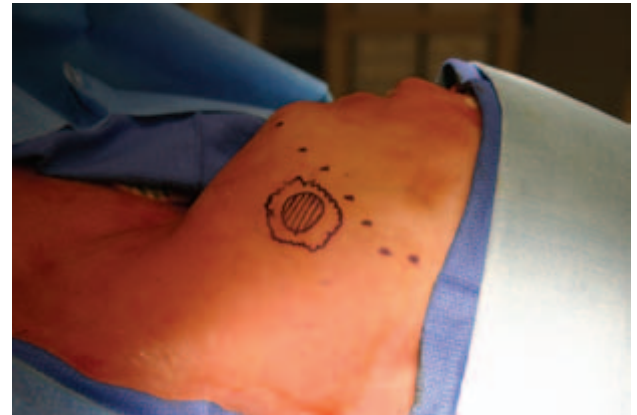
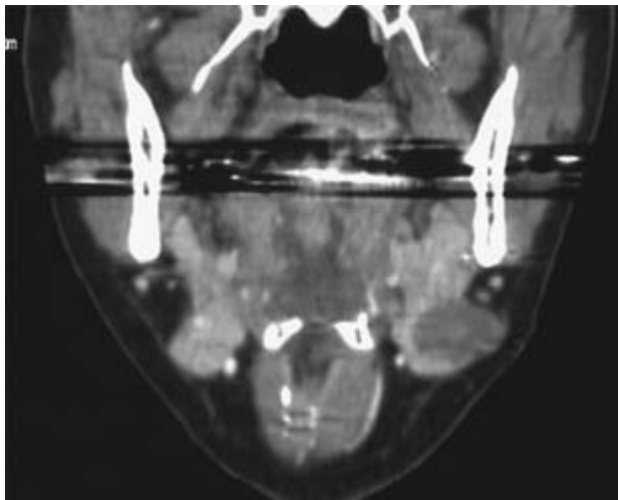
**Figure 9.8a.** Axial CT shows tumor projecting beyond the gland surface.



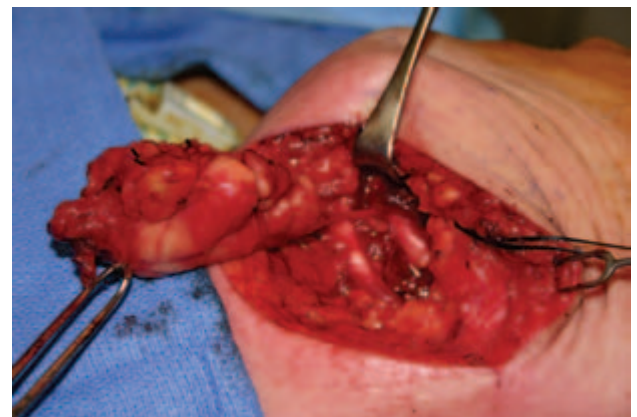**Figure 9.8c.** High-power axial CT scan shows the tumor marked with a circle.



**Figure 9.8d.** Operative picture showing the tumor marked by palpation.



**Figure 9.8b.** Coronal CT confirms the surface involvement.



**Figure 9.8e.** Intraoperative view of extracapsular dissection preserving soft tissue over the tumor surface.