

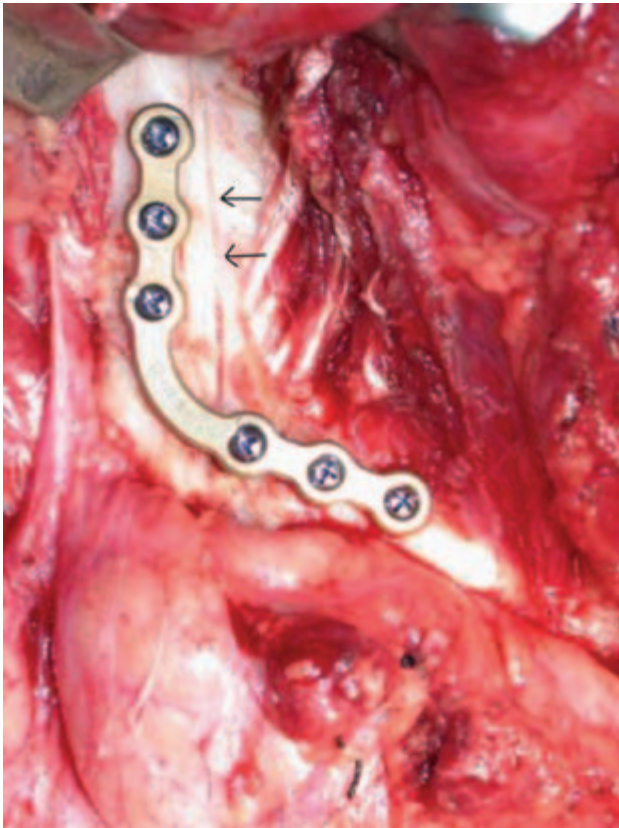Figure 8.8d. The mandible is accessed via a cervical incision from mastoid to chin without lip split. Subsigmoid osteotomy cut marked with saw through buccal cortex only (arrows) and plate has been applied prior to completing the osteotomy.

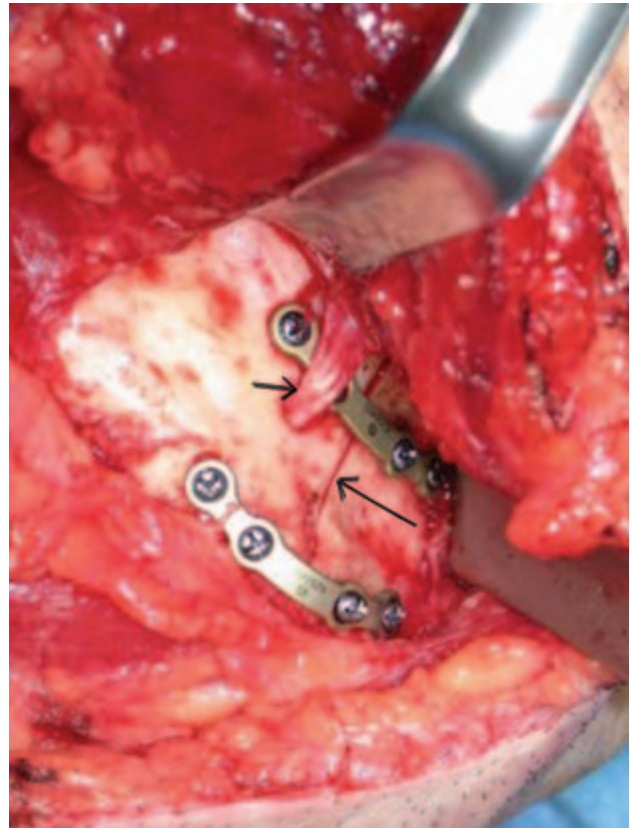


Figure 8.8e. Osteotomy marked with a saw through the buccal cortex (long arrow) anterior to the mental nerve (short arrow). Two miniplates applied prior to completing the osteotomy.

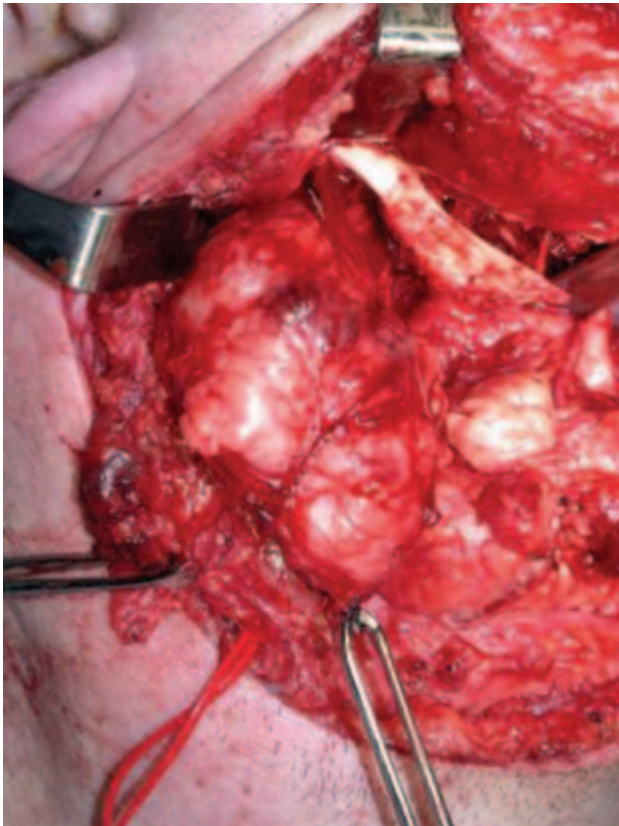


Figure 8.8f. The plates are removed, the double osteotomy is completed, and the osteotomized hemimandible is retracted upward and rotated to expose the lateral pharyngeal space, and the tumor is being delivered under direct vision.