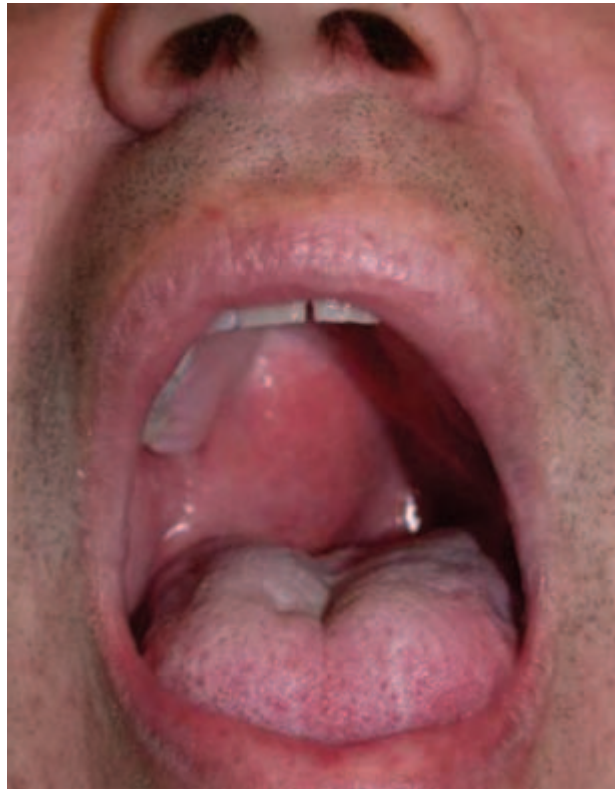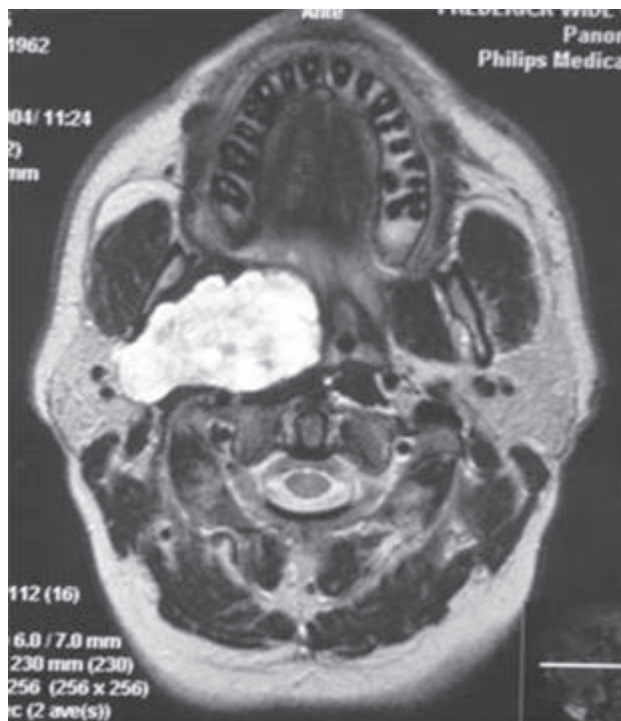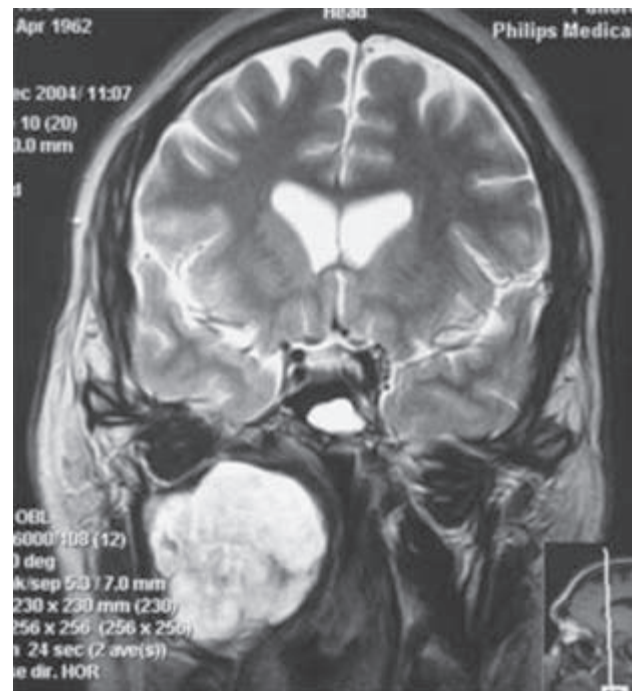


Figure 8.8a. Deep lobe parotid tumor with parapharyngeal extension presenting as a palatal mass.



b



c

Figures 8.8b and 8.8c. Axial and coronal CT scans show the tumor in the lateral pharyngeal space.