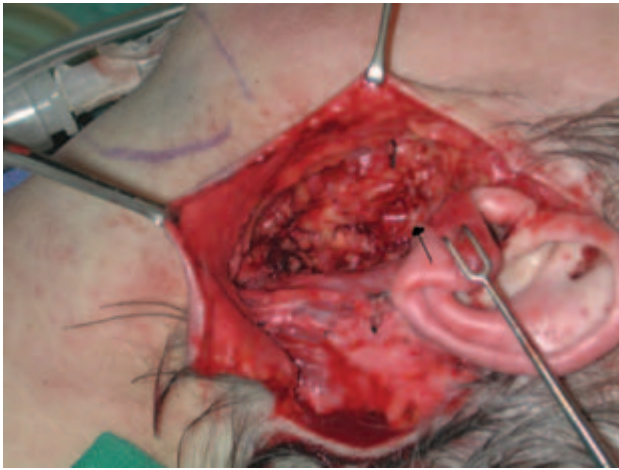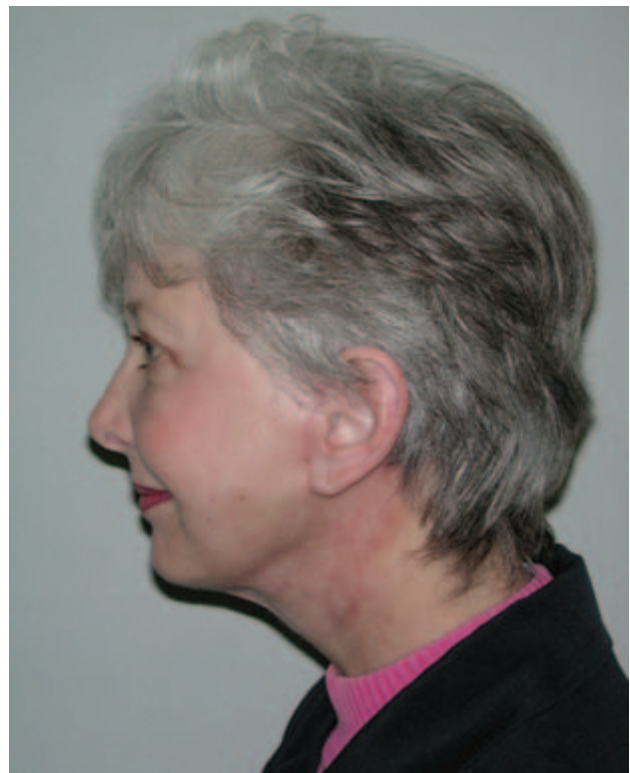


**Figure 8.5c.** Surgical access through face lift incision running into occipital hair line. Arrow shows facial nerve trunk being dissected.



d



e

**Figures 8.5d and 8.5e.** Six months postoperatively. Notice absence of neck incision. (Aesthetic portions of this case undertaken by Dr. A. Pazoki, DDS, MD.)