



a

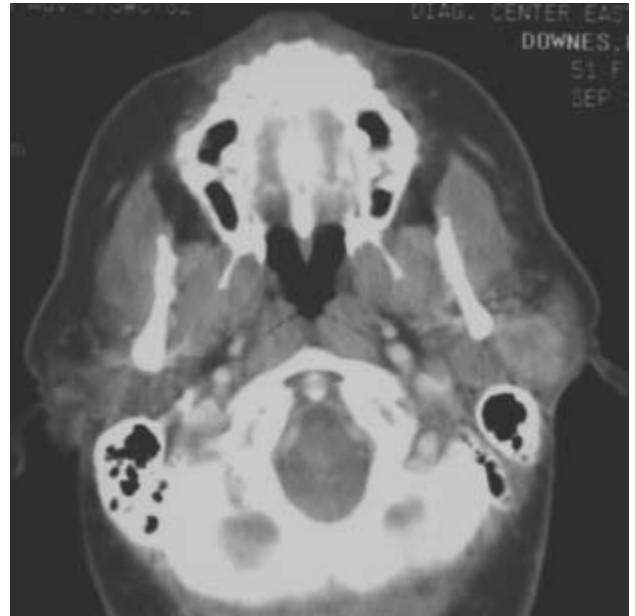


Figure 8.4c. CT scan of left parotid showing superficial lobe tumor.



b

Figures 8.4a and 8.4b. Patient with pleomorphic adenoma of the left parotid gland preoperatively.

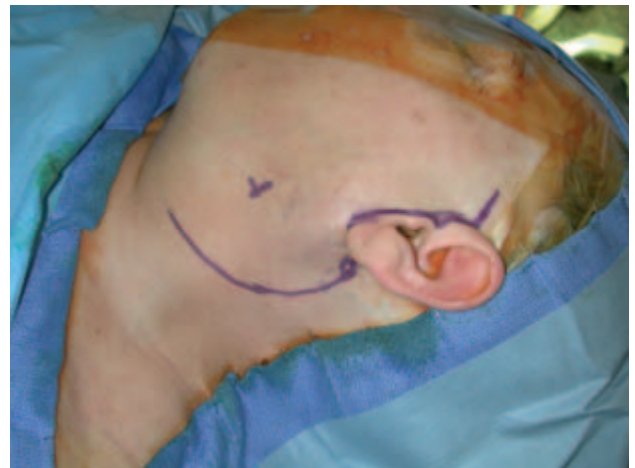

Figure 8.4d. Modified Blair incision.