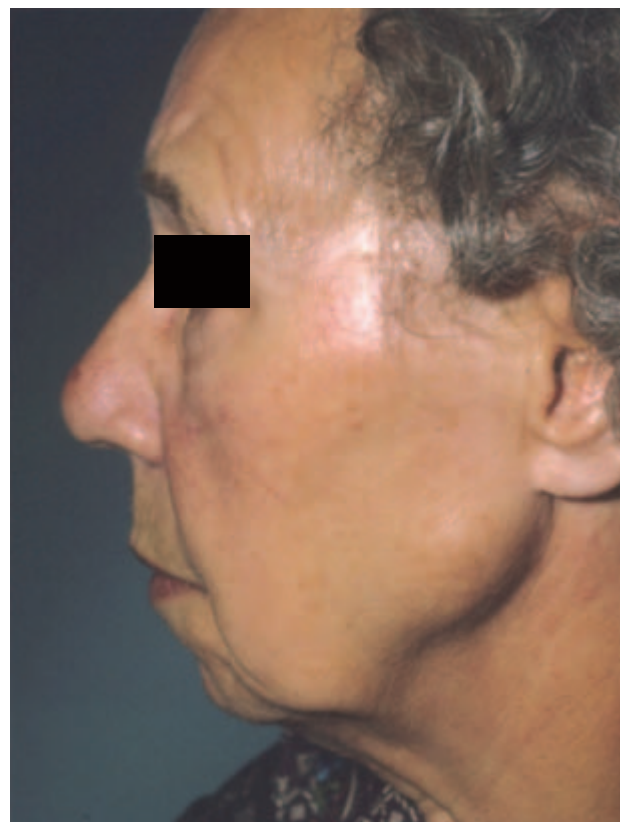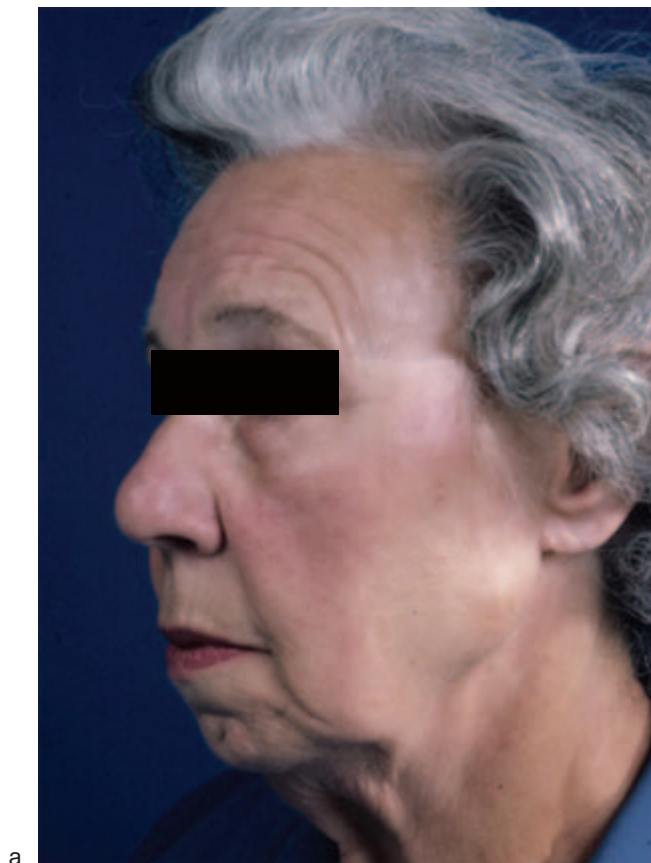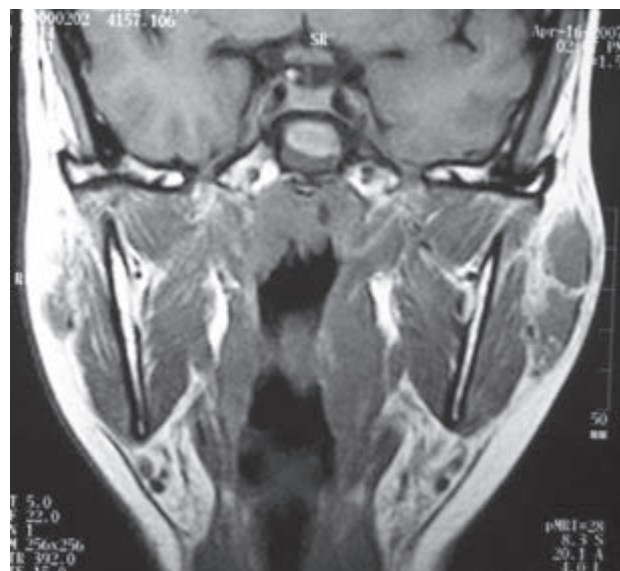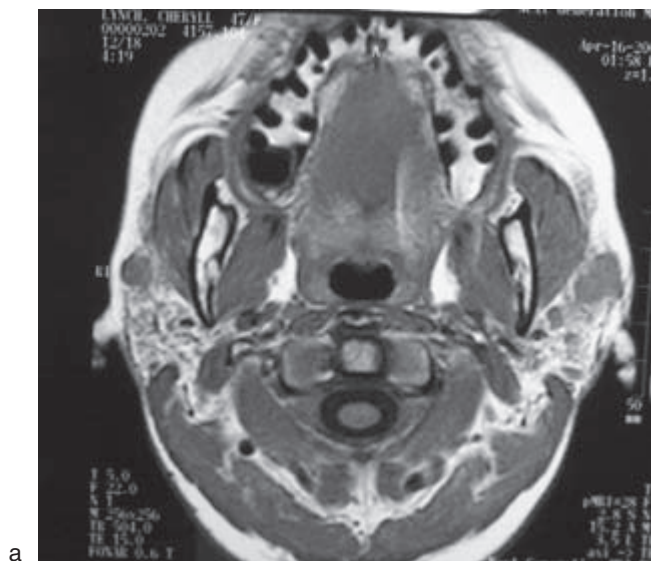


**Figures 6.3a and 6.3b.** A 75-year-old woman with a left parotid mass. Fine needle aspiration biopsy suggested lymphoma, leading to superficial parotidectomy. Histopathology identified benign lymphoepithelial lesion.



**Figures 6.4a and 6.4b.** A 45-year-old woman diagnosed with Sjogren's syndrome with bilateral parotid lesions shown on axial (a) and coronal images (b).